

# Electromyography in Strabismus

**EDWARD TAMLER, M.D., ARTHUR JAMPOLSKY, M.D., and  
ELWIN MARG, Ph.D., San Francisco**

ELECTROMYOGRAPHY of human extraocular muscles is proving to be a technique of great value in elucidating the nature of normal ocular motility.<sup>2,3,6,7,8</sup> However, in the field of strabismus, whether paralytic or nonparalytic, it offers very little practical help in diagnosis and treatment at the present time.

Briefly the procedure<sup>5</sup> (schematically represented in Figure 1) is as follows: The patient is placed on a wheeled stretcher in a room that is screened to keep out extraneous electrical impulses that might contaminate the electromyogram. Using topical anesthesia only, fine electrodes are inserted through the conjunctiva into the extraocular muscles to be tested. The electrical activity of the muscle is carried via a headband and cables to an amplifying system which, in turn, sends the amplified impulses to an oscilloscope. The display on the face of the oscilloscope is photographed by a variable film speed camera.

Electrical activity of the muscle is also carried to a loudspeaker for auditory monitoring. This guides the investigator in determining whether he has a satisfactory insertion in the muscle. When the insertion is adequate, a loud rumbling or crackling noise, rising to a crescendo, will be heard as the eye moves into the field of action of the involved muscle.

The investigator wears a lapel microphone, into which he dictates the conditions noted as the test is being performed. This dictated protocol of the test is recorded on tape. Later, when the results of the test are analyzed, the film record and the narrative are synchronized so that the reviewer can consider the electromyogram and the investigators' comments together. Figure 2, a typical electromyogram obtained by this technique, shows a simultaneous recording of the electrical activity of four extraocular muscles.

Investigations into the applications of electromyography to comitant (nonparalytic) strabismus are hindered by the dearth of suitable subjects. Most of the available subjects with comitant strabismus are children, who cannot be considered suitable for a technique requiring insertion of needles into the eye muscles under topical anesthesia. Deeper anesthesia is not feasible, for it would alter the condi-

• **Electromyography of the human extraocular muscles is a new research tool designed to elucidate many problems in ocular physiology. Although at present it affords little clinical help in the diagnosis and treatment of strabismus, it may in time be of value in neuro-ophthalmologic disease.**

tions of the test and vitiate the findings. In the occasional case in which an adult subject with comitant strabismus became available for testing, no significant difference in extraocular muscle electrical activity as compared with that of normal subjects was noted. This was to be expected inasmuch as extraocular electromyography reflects primarily the peripheral extraocular muscle activity rather than central mechanisms, which is a further obstacle to the clinical use of electromyography in comitant strabismus.

There are also obstacles to the application of electromyography to noncomitant strabismus. As with comitant strabismus, one is the fact that electromyography informs primarily of the peripheral activity of the neuromuscular extraocular system. This limits conclusions that may be drawn from electromyograms regarding more central mechanisms or etiologic factors. For example, Breinin<sup>1</sup> attempted to explain the "A-V" syndrome\* on the basis of changes in activity of the horizontal recti during vertical movements. He observed that in most of the ten cases of the A-V syndrome in which he carried out the tests the horizontal recti showed innervational changes corresponding to the deviation, although in a few of this group the horizontal recti showed no particular change in vertical gaze. From this, he concluded that the horizontal recti must play some part in the varying angle of strabismus and that in surgical treatment it is advisable to deal first with the horizontal muscles, then the vertical. Such a conclusion may be misleading, for the mere fact of increased activity of a muscle may be owing only to the new position of the eye and give no information as to why the eye moved to this new position. For example, in exophoria if the divergent eye is covered it will deviate outward and the electromyogram will show increased activity of the lateral rectus of that eye (Figure 2), but it cannot be concluded from this

From the Division of Ophthalmology, Department of Surgery, Stanford University School of Medicine, San Francisco. This study was aided by funds provided under Public Health Service Grant B686 and Office of Naval Research Contract, NONR 225 (20).

Presented as part of a Panel Discussion on Strabismus before the Section on Eye at the 88th Annual Session of the California Medical Association, San Francisco, February 22 to 25, 1959.

\*The term takes its name from the shape of the letters A and V: There is horizontal incomitance in vertical movements of the eye, vertical incomitance in cardinal direction movements.

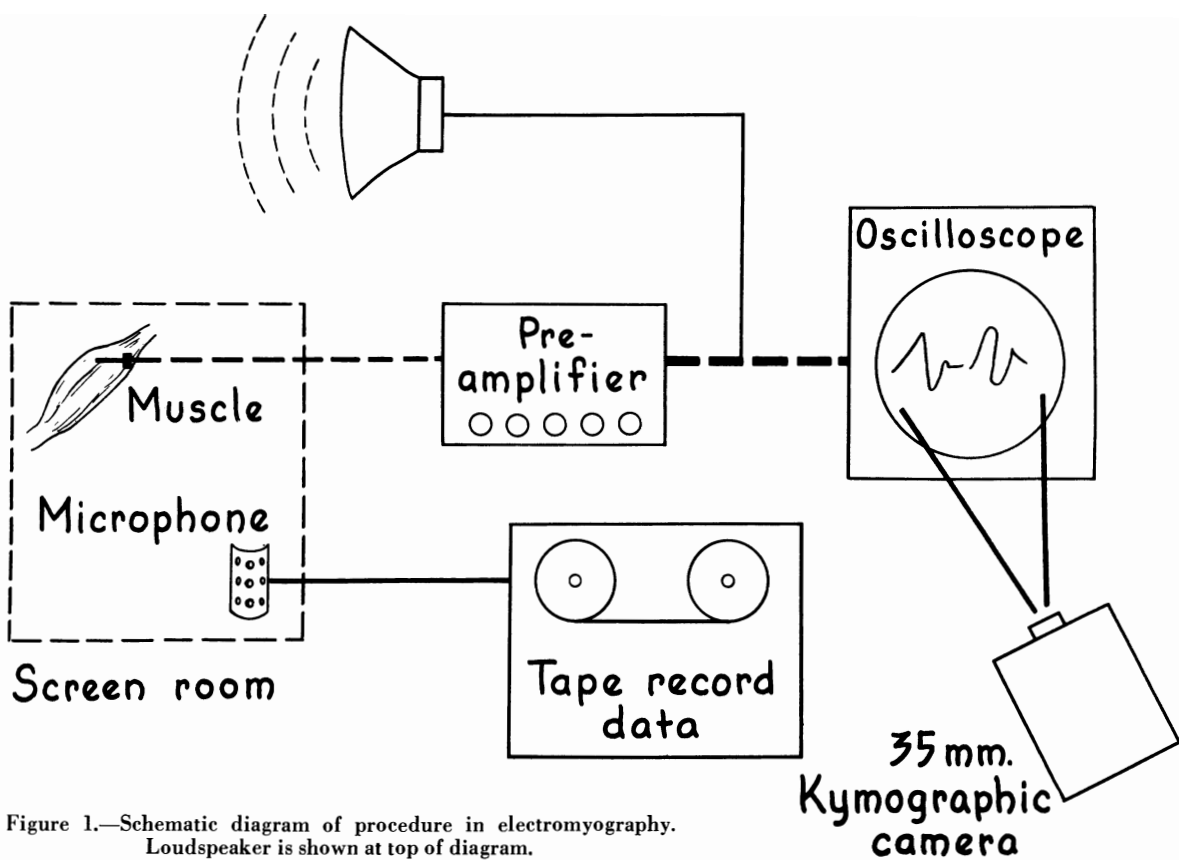


Figure 1.—Schematic diagram of procedure in electromyography. Loudspeaker is shown at top of diagram.

that an abnormally overactive lateral rectus caused exophoria. Similarly, in the A-V syndrome the electrical activity of the horizontal muscles in vertical movements may merely reflect the changing horizontal alignment of the eyes rather than indicate the cause of the horizontal incomitance. Furthermore, horizontal recti activity during vertical movements may vary greatly between one normal subject and another. In Figure 3 the right lateral rectus shows greater activity in the up and right position of gaze than in the down and right position. In another subject the right lateral rectus was more active in down and right gaze than in the up and right gaze (Figure 4).

Another obstacle to the application of electromyography to paralytic strabismus is the relatively small number of patients with a neuro-ophthalmologic defect of specific type. Although reports have been made of abnormal electromyograms in conditions such as diabetic neuropathy, aberrant regeneration, Duane's syndrome, endocrine exophthalmus, ophthalmoplegia, Moebius' disease, and superior oblique tendon sheath syndrome, it cannot properly be inferred from these few cases that the patterns observed are characteristic. At present an abnormal electromyogram in neuro-ophthalmological disease merely confirms the presence of neuropathy or myopathy.

With regard to the diagnosis of extraocular muscle palsy, it should be pointed out that the relative strength of a muscle cannot be judged by the amplitude of the electromyographic tracing except in pro-

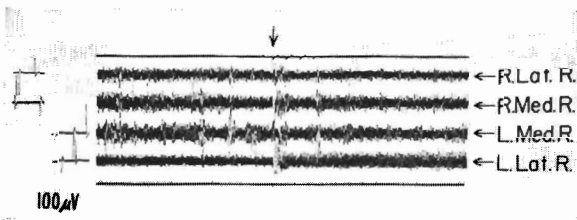


Figure 2.—Simultaneous recording of four extraocular muscles. Calibration is at left (the deflection represents 100 microvolts), signal marker is on top line, and time scale is at the bottom, in this and succeeding figures. Arrow indicates moment of covering the left eye of a subject who had exodeviation. Note the increased activity of the left lateral rectus muscle as the left eye moves outward, while the right eye maintains steady fixation.




Figure 3.—Electromyogram made as the right eye was moving from down and right gaze to up and right gaze. Note increased electrical activity of right lateral rectus (right half of tracing) as eye moved into upper field of gaze.

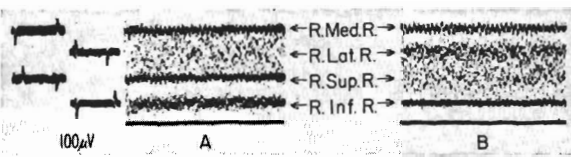


Figure 4.—*A*, Tracings made with the right eye in down and right gaze. *B*, The same eye, a moment later, in up and right gaze. Note increased right lateral rectus activity in the lower field of gaze (widely spread tracing of right lateral rectus lead in *A* as compared with somewhat more concentrated markings in corresponding tracing in *B*).



Figure 5.—Tracings from three electrodes in the same eye muscle as the muscle contracted. Note the variability in amplitude and speed of response from electrode to electrode. Channel 2 was not recording.

nounced paralysis. Even in normal conditions the amplitude may vary, depending on several factors, principally the location and depth of the inserted electrode. Figure 5 shows tracings from three electrodes that were inserted into the same normal eye muscle during contraction of that muscle; there were considerable disparities. Electrodes closer to the belly of the muscle record activity sooner and reach larger amplitudes than the recordings from electrode tips more distant from the muscle belly.




Figure 6.—Tracing made as the left eye was moving from primary position to up and right gaze and then attempted to move to up and left gaze. Response in the left superior rectus muscle was normal in spite of the fact that the left eye failed to move up and out.

Despite the obstacles, there are a few clinical applications of electromyography to paralytic strabismus. For example, there is enough evidence now to state that distinction can be made between limitation of eye movement due to mechanical restriction and that due to nerve damage. Figure 6 is an electromyogram of the left superior rectus muscle of a 17-year-old boy who received trauma to the left orbit that resulted in inability to move the left eye up and out. As the tracing indicated no abnormality, innervation and muscle contraction were considered normal, which suggested the impaired motility was owing to mechanical restriction. Operation was performed and scar tissue adhesions involving the muscle were excised. Rotation to the up and out position was possible thereafter. An electromyogram after operation was the same as the one made before operation.



Figure 7.—Increase in activity of involved left lateral rectus muscle (as shown by increase in amplitude of waves, beginning about midway of tracing) in patient with myasthenia gravis approximately 20 seconds after intravenous injection of 10 mg. of edrophonium chloride.

Another application is in the diagnosis of myasthenia gravis. It appears that ocular electromyography is the most sensitive test for the response of the muscles to a test dose of edrophonium chloride (Tensilon®). Figure 7 shows the increase in electrical activity in an involved muscle in a patient with myasthenia gravis about 20 seconds after the intravenous injection of 10 mg. of edrophonium chloride. Electromyography may decide the diagnosis in patients who have false negative response to the other usual clinical tests.

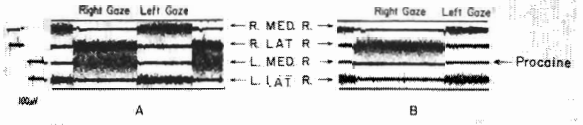


Figure 8.—*A*, When these tracings were made, the right eye was performing saccades (rapid versions) to right and left. *B*, The same eye was performing the same movements after procaine-induced paralysis of the left medial rectus. Note greater activity of right lateral rectus (yoke muscle of paralyzed muscle) in saccades to the right in *B* as compared with *A*.

Ocular electromyography also gives objective confirmation of the over-action of a yoke muscle in a paralytic strabismus. This is illustrated in an electromyogram in a case in which the paralysis was artificially induced by injection of procaine (Figure 8).

REFERENCES

1. Breinin, G. M.: New aspects of ophthalmoneurologic diagnoses, *Arch. Ophth.*, 58:375, 1957.
2. Jampolsky, A., Marg, E., and Tamler, E.: An electromyographic study of divergence mechanisms. To be published.
3. Jampolsky, A., Navratzki, I., and Tamler, E.: An electromyographic study of procaine-induced paralysis of extraocular muscles. To be published.
4. Jampolsky, A., Marg, E., and Tamler, E.: Artefacts and normal variations in human extraocular electromyography, *Arch. Ophth.*, 61:402, 1959.
5. Marg, E., Jampolsky, A., and Tamler, E.: Elements in the technique of human extraocular electromyography, *Arch. Ophth.*, 61:258, 1959.
6. Tamler, E., Jampolsky, A., and Marg, E.: An electromyographic study of coactivity of human extraocular muscles in following movements, *Arch. Ophth.*, 61:270, 1959.
7. Tamler, E., Marg, E., and Jampolsky, A.: Electromyography of human saccadic eye movements. To be published.
8. Tamler, E., Jampolsky, A., and Marg, E.: An electromyographic study of following movements of the eye between tertiary positions. To be published.

Eye Research, Stanford University Hospitals, San Francisco 15 (Tamler).